

# Management of Acute Osteoporotic Vertebral Fractures: A Nonrandomized Trial Comparing Percutaneous Vertebroplasty with Conservative Therapy

Terrence H. Diamond, MD, Bernard Champion, MD, William A. Clark, MD\*

**PURPOSE:** We sought to determine whether percutaneous vertebroplasty—which involves the injection of cement to stabilize a fractured vertebral body—may be an effective treatment for vertebral fracture.

**METHODS:** We enrolled 79 consecutive osteoporotic patients (24 men and 55 women; ages 51 to 93 years) presenting with acute vertebral fractures. Clinical characteristics and bone densitometry were measured at baseline. Pain scores (on a 0 to 25 scale) and levels of function (on a 0 to 20 scale) were recorded on presentation, at 24 hours, at 6 weeks, and 6 to 12 months after therapy.

**RESULTS:** Fifty-five patients (70%) were treated by percutaneous vertebroplasty and 24 (30%) were treated by conservative therapy alone. They were followed for a mean of 215 days (range, 57 to 399 days). The baseline clinical characteristics, bone densitometry, and fracture data were similar in the two groups. Twenty-four hours after vertebroplasty, there was a

53% reduction in pain scores (from 19 to 9;  $P = 0.0001$ ) and a 29% improvement in physical functioning (from 14 to 18;  $P = 0.0001$ ), whereas pain scores and physical functioning remained unchanged at 24 hours in the patients treated conservatively (both  $P = 0.0001$  compared with the changes after percutaneous vertebroplasty). Thirteen patients (24%) treated by percutaneous vertebroplasty were able to cease all analgesia after 24 hours ( $P = 0.0001$  compared with none of the 24 patients treated conservatively). Clinical outcomes at 6 weeks and 6 to 12 months were similar in both groups.

**CONCLUSION:** When compared with conservative therapy, percutaneous vertebroplasty results in prompt pain relief and rapid rehabilitation. In experienced hands, it is a safe and effective procedure for treating acute osteoporotic vertebral compression fractures. *Am J Med.* 2003;114:257–265. ©2003 by Excerpta Medica Inc.

Acute osteoporotic vertebral fracture may be a crippling disorder causing severe back pain with associated morbidity and prolonged hospitalization (1,2). Percutaneous vertebroplasty has been an important advance in the management of this syndrome (3–14), but has invoked both enthusiasm and controversy (15,16), in part because the technique has not been compared with other forms of therapy. In this nonrandomized study, we compared the clinical outcomes of 55 osteoporotic patients who underwent percutaneous vertebroplasty with 24 patients who refused percutaneous vertebroplasty and were managed conservatively.

## METHODS

### *Patients and Eligibility*

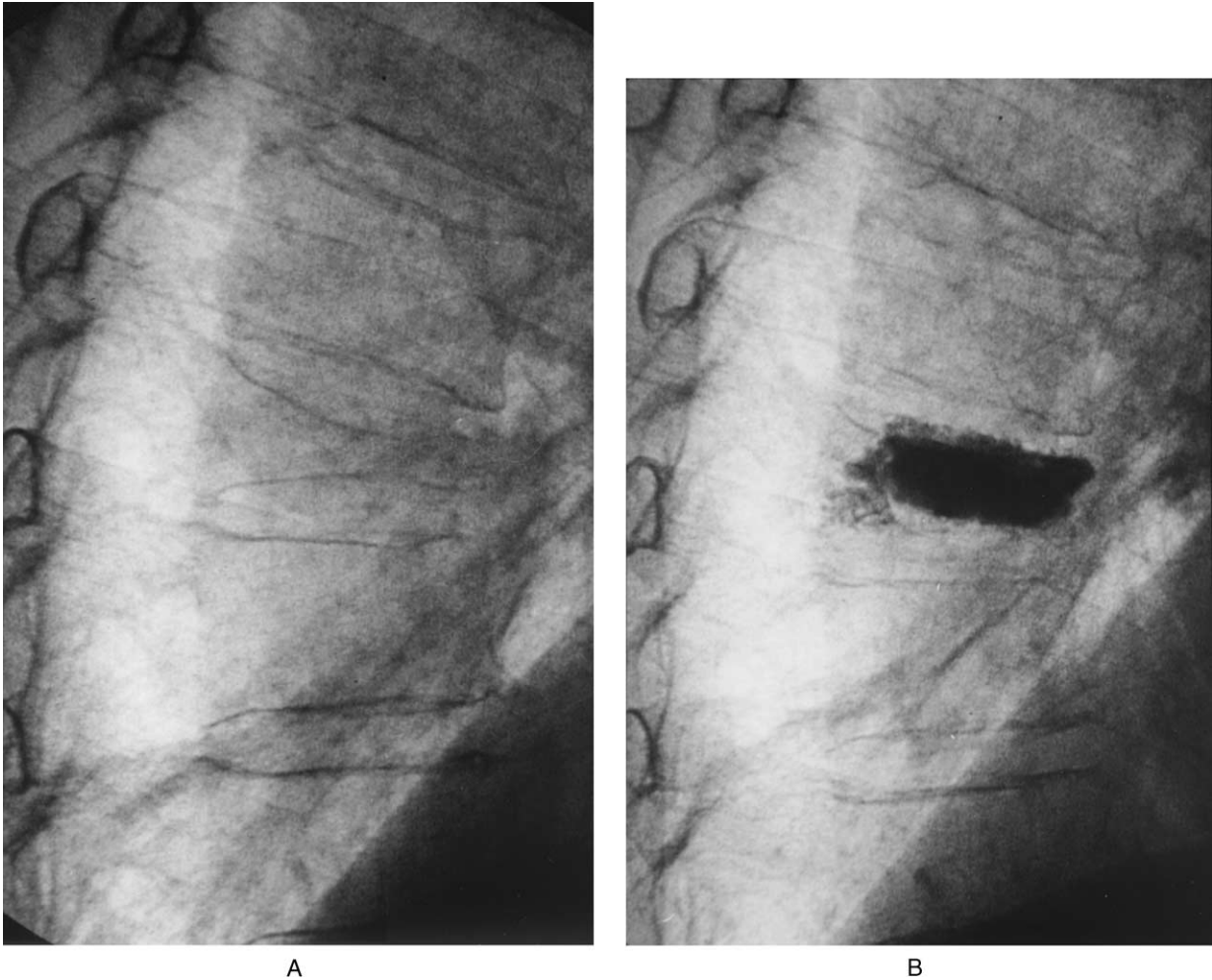
All patients presenting to the emergency department ( $n = 37$ ) of, or admitted as inpatients ( $n = 42$ ) to, The Saint George Hospital from November 2000 to December 2001 with acute vertebral fracture syndrome were considered for the study. Inclusion criteria were acute severe vertebral fracture pain, densitometric evidence of osteoporosis, and acute fracture activity on magnetic resonance imaging or technetium-99m bone scan. Exclusion criteria were pathologic fracture due to myeloma/metastasis, osteomyelitis, major retropulsion of bony fragments into the spinal canal, and coagulopathy. We included 2 men with cancer (1 with Hodgkin's lymphoma and the other with renal cell carcinoma) who had back pain due to osteoporotic fractures. Patients had a 1- to 6-week history of incapacitating pain that was not relieved by nonopiate analgesia. Their clinical characteristics, including smoking history, alcohol intake, corticosteroid use (greater than 5 mg of prednisone equivalent per day), and thyroxine therapy, were recorded. Vitamin D and parathyroid hormone levels were measured using

From the Departments of Endocrinology (THD, BC) and Radiology (WAC), Saint George Hospital Campus, University of New South Wales, Sydney, Australia.

\*Dr. Clark is employed as an interventional radiologist by Mayne Health Diagnostics, Saint George Private Hospital, Sydney, Australia.

Requests for reprints should be addressed to Terrence H. Diamond, MD, Department of Endocrinology, Saint George Hospital, Gray Street, NSW 2217, Sydney, Australia, or [terrydiamond@optushome.com.au](mailto:terrydiamond@optushome.com.au).

Manuscript submitted February 28, 2002, and accepted in revised form August 16, 2002.



**Figure 1.** Lateral radiograph demonstrating a vertebral compression fracture before (A) and after (B) the injection of cement by percutaneous vertebroplasty.

standard assays (17). Vitamin D deficiency was defined as serum 25-hydroxyvitamin D concentrations less than 30 nmol/L, and secondary hyperparathyroidism was defined as serum parathyroid hormone concentrations greater than 7.5 pmol/L. Bone densitometry was measured by dual-energy X-ray absorptiometry using a Lunar DPX-L densitometer (Lunar Corporation, Madison, Wisconsin) (17). Osteoporosis was defined as a lumbar spine or femoral neck bone mineral density T-score greater than 2.5 SD below a healthy normal Australian reference range. Spinal radiography was used to determine the degree of vertebral compression (18). The study was performed according to the guidelines of the National Health and Medical Research Council.

### *Intervention*

Percutaneous vertebroplasty was offered to all patients meeting the inclusion criteria. Those consenting were assessed by magnetic resonance imaging to confirm the

presence of acute fracture edema (defined as a high signal on short tau inversion recover [STIR] sequences).

Percutaneous vertebroplasty was performed via transpedicular approach using local anesthesia (1% lidocaine) (12,18). A total volume of 1 to 6 mL of polymethylmethacrylate was injected into the body of the fractured vertebra under careful fluoroscopic control. Figure 1 shows a radiograph of an acute spinal fracture, before and after percutaneous vertebroplasty.

Patients who declined percutaneous vertebroplasty and who agreed to longitudinal evaluation constituted our control group. Fifteen (65%) of these patients agreed to undergo magnetic resonance imaging.

All patients were offered similar analgesia, comprising opiates such as oral morphine sulfate (5 to 30 mg twice daily) or pethidine injections, cyclooxygenase inhibitors, hot packs, and gentle mobilization. Breakthrough pain was managed with oral paracetamol (500 to 1000 mg every 4 to 6 hours). Pain management was titrated ac-

**Table 1.** Characteristics of Patients with Acute Vertebral Fractures, Stratified by Treatment (Vertebroplasty versus Conservative Therapy)

Characteristic	Treatment		P Value
	Percutaneous Vertebroplasty (n = 55)	Conservative Therapy (n = 24)	
	Number (%) or Mean $\pm$ SD		
Male sex	20 (36)	4 (17)	0.08
Inpatients	29 (53)	13 (54)	0.90
Age (years)	76.5 $\pm$ 9.3	76.3 $\pm$ 10	0.95
Weight (kg)	64.6 $\pm$ 12.4	69.1 $\pm$ 19.1	0.22
Height (cm)	159.8 $\pm$ 8.8	157.6 $\pm$ 6.4	0.27
Smoking	6 (11)	2 (8)	0.73
Alcohol excess	7 (13)	2 (8)	0.57
Corticosteroid therapy	15 (27)	2 (8)	0.06
Vitamin D deficiency	33 (60)	19 (79)	0.10
Secondary hyperparathyroidism	19 (35)	13 (54)	0.10
Lumbar spine T-score	-3.9 $\pm$ 1.1	-3.5 $\pm$ 1.5	0.19
Femoral neck T-score	-2.7 $\pm$ 1.1	-2.5 $\pm$ 1.5	0.62
Previous vertebral fractures	3.5 $\pm$ 2.3	3.0 $\pm$ 1.4	0.33
Follow-up (days)	221 $\pm$ 95	181 $\pm$ 17	0.12

ording to the patient's needs. All patients also received antiosteoporotic medications, such as oral alendronate (70 mg weekly; n = 25) or intravenous pamidronate (60 mg, 6 monthly; n = 54), together with elemental calcium

(1200 mg daily) and ergocalciferol (0.25  $\mu$ g daily) if they were vitamin D deficient. Pamidronate was selected for patients with corticosteroid-induced osteoporosis or those who were intolerant to alendronate.

**Table 2.** Changes in Pain Score and Physical Functioning in Patients with Acute Vertebral Fractures, by Type of Treatment

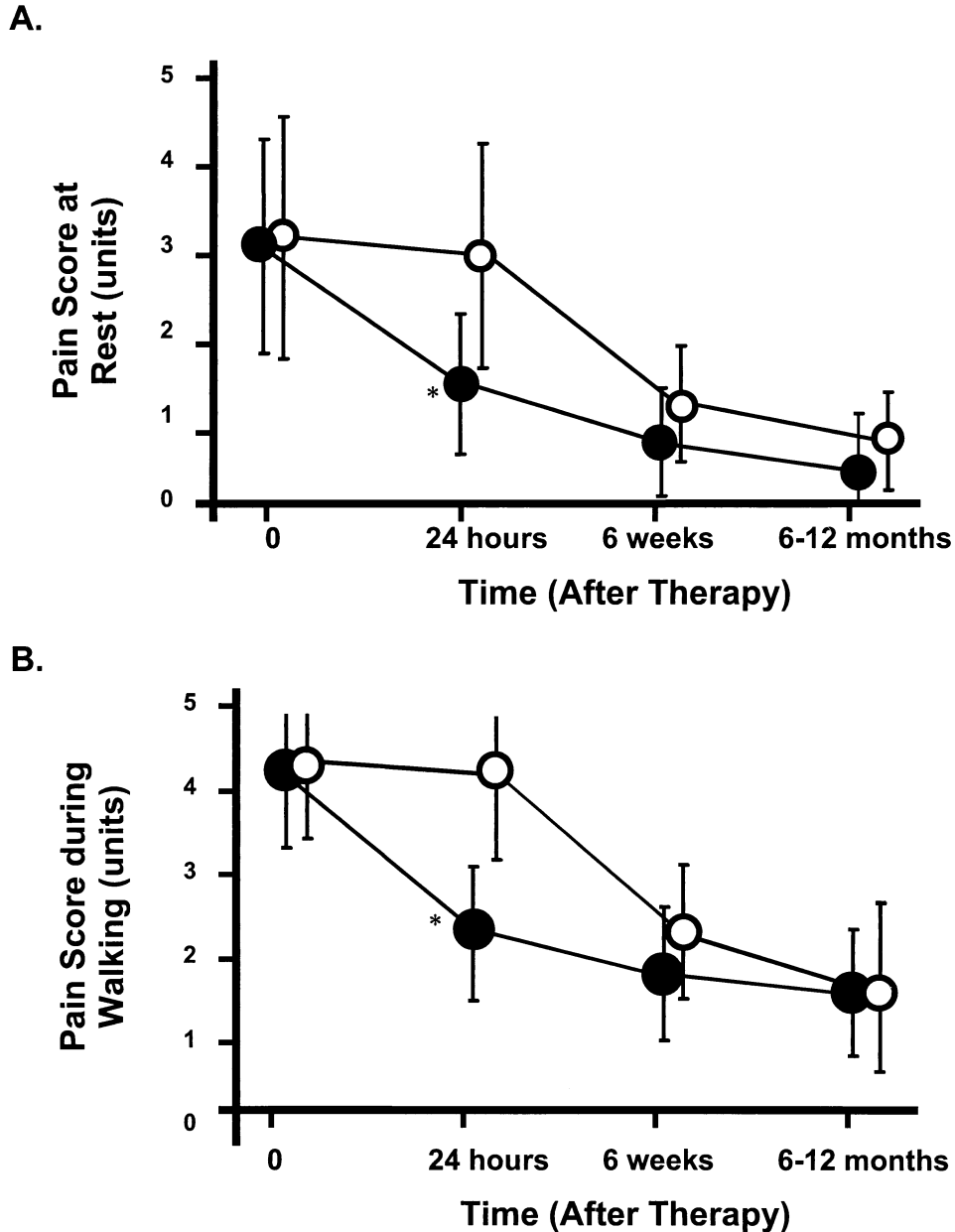
	Treatment		P Value*
	Percutaneous Vertebroplasty	Conservative Therapy	
<i>Pain scores</i>			
Baseline <sup>†</sup>	19 $\pm$ 4	20 $\pm$ 5	0.99
24 hours	9 $\pm$ 5 <sup>‡</sup>	19 $\pm$ 6	0.0001
(% change from baseline)	-53%	-5%	0.0001
6 weeks	5 $\pm$ 4 <sup>‡</sup>	7 $\pm$ 5 <sup>§</sup>	0.24
(% change from baseline)	-72%	-61%	0.15
6-12 months	4 $\pm$ 4 <sup>‡</sup>	4 $\pm$ 6 <sup>§</sup>	0.97
(% change from baseline)	-77%	-71%	0.57
<i>Physical functioning</i>			
Baseline <sup>†</sup>	14 $\pm$ 4	13 $\pm$ 5	0.29
24 hours	18 $\pm$ 3 <sup>‡</sup>	13 $\pm$ 5	0.0001
(% change from baseline)	+29%	0%	0.0001
6 weeks	19 $\pm$ 2 <sup>‡</sup>	17 $\pm$ 4 <sup>§</sup>	0.02
(% change from baseline)	+36%	+31%	0.29
6-12 months	19 $\pm$ 1 <sup>‡</sup>	18 $\pm$ 3 <sup>§</sup>	0.02
(% change from baseline)	+36%	+39%	0.22

\* For between-group comparison.

<sup>†</sup> Day of vertebroplasty or day of enrollment in study.

<sup>‡</sup> P < 0.0001 compared with measurements before percutaneous vertebroplasty.

<sup>§</sup> P < 0.0001 compared with measurements at 24 hours after commencing conservative therapy.



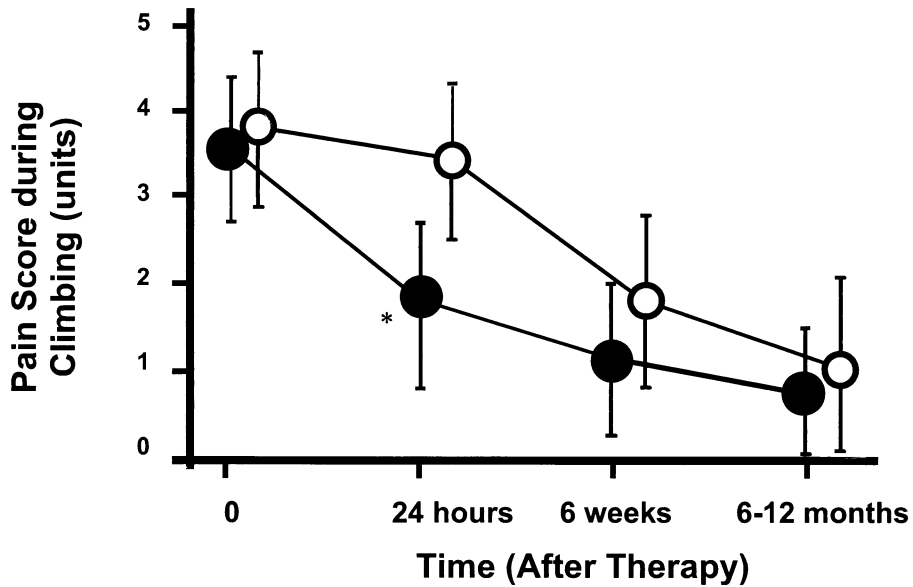
**Figure 2.** Longitudinal changes in the mean ( $\pm$  SD) pain scores (as measured by a visual analog scale) for each of the five individual activities (A = at rest, B = walking, C = climbing, D = bathing, and E = dressing). Patients treated by percutaneous vertebroplasty (solid circles) are compared with patients treated conservatively (empty circles). Comparisons are made by analysis of variance with a post hoc Tukey test. The asterisk (\*) indicates  $P < 0.0001$  for between-group comparisons.

**Outcome Assessment**

Complications, visual analog pain score (11,19), and the Barthel index (11,20) level of function were assessed on presentation, at 24 hours, at 6 weeks, and 6 to 12 months after therapy. These times were calculated from the day of vertebroplasty in the interventional group or the day of enrollment in the study (within 72 hours of hospital admission) in the conservatively treated group. Length of hospital stay was recorded for all patients.

The visual analog pain score (11,19) utilizes a visual scale from 0 (no pain) to 5 (maximal pain). The patient records the level of pain associated with each of five activities: walking, climbing in and out of a chair, bathing, dressing, and at rest. The score is recorded immediately on awakening, before the administration of the morning dose of analgesia. The total score represents the sum of all five scores (on a 0 to 25 scale). The Barthel index (11,20) is recorded at the same time. This comprises 10 questions

C.



D.

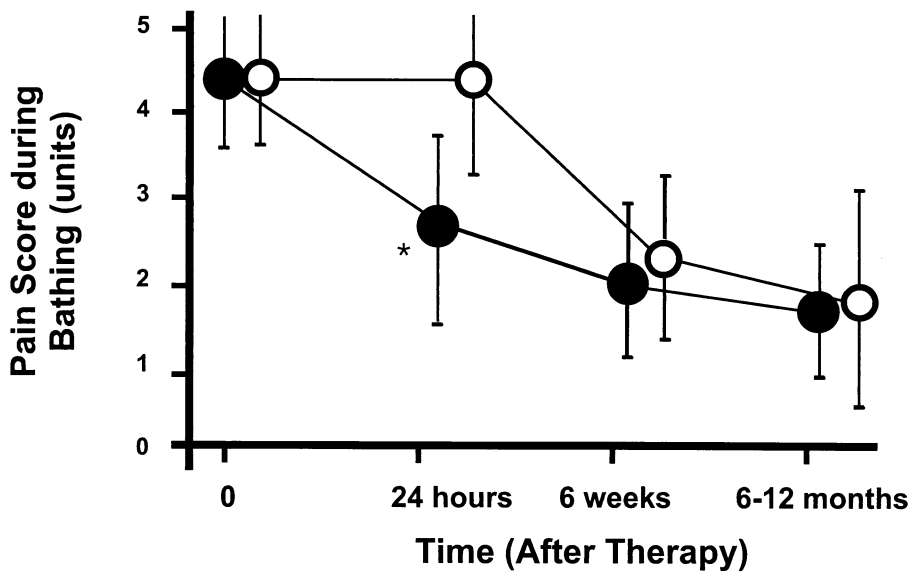


Figure 2. Continued.

pertaining to activities of daily living, such as mobility, bathing, dressing, grooming, feeding, toilet activities, climbing stairs, and transferring (moving from a bed to a chair, or sitting, unaided). The lower the score on a 0 to 20 scale, the worse the disability.

Analgesic requirements were calculated at the same time. While no logbooks were kept, estimates of analgesic intake were recorded as “stopped”, “greater than 50% reduction in dosage,” or “no change.”

### Statistical Analysis

Groups were compared using the chi-squared test, paired or unpaired Student *t* tests, or the Mann-Whitney *U* test, as appropriate. Outcomes measured at several times were compared using analysis of variance, with post hoc Tukey test. Variables were corrected for baseline values by subtracting the follow-up measurement from the baseline value, and expressing the difference as a percentage of the baseline value.

E.

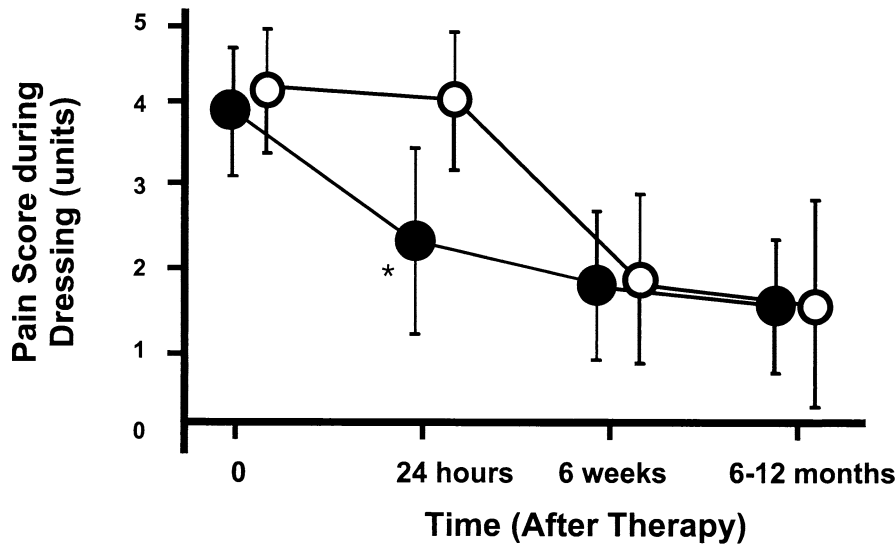


Figure 2. Continued.

## RESULTS

The 24 men (30%) and 55 women (77%) in the study were followed for a mean of 215 days (range, 57 to 399 days), and they ranged from 51 to 93 years in age. Percutaneous vertebroplasty was performed in 55 patients (70%) on 71 vertebrae, including 45 thoracic vertebrae (T5 = 3, T6 = 2, T7 = 6, T8 = 11, T9 = 11, T10 = 2, T11 = 2, and T12 = 8) and 26 lumbar vertebrae (L1 = 8, L2 = 6, L3 = 5, L4 = 3, and L5 = 4). One vertebra was injected in 42 patients, two vertebrae in 11 patients, three vertebrae in 1 patient, and four vertebrae in 1 patient. The degree of vertebral compression in the vertebroplasty group was 40% (range, 10% to 80%), similar to that in the control group.

Minor complications were noted in 3 patients after vertebroplasty, including a fractured transverse process in 2 patients and a hemorrhage into the psoas muscle in 1 patient in whom subcutaneous heparin had been continued inadvertently on the day of the procedure. Three patients treated with vertebroplasty developed recurrent back pain due to new vertebral fractures within 6 weeks of undergoing percutaneous vertebroplasty. The positions of the new fractures were at least two vertebral bodies distant from the vertebroplasty sites.

Patients who underwent vertebroplasty had similar characteristics to those who refused the procedure (Table 1). Vitamin D deficiency was common in both groups. Two men treated by percutaneous vertebroplasty and 3 women treated conservatively died within 6 months of their fractures ( $P = 0.14$ ).

## Changes in Pain Score and Physical Function

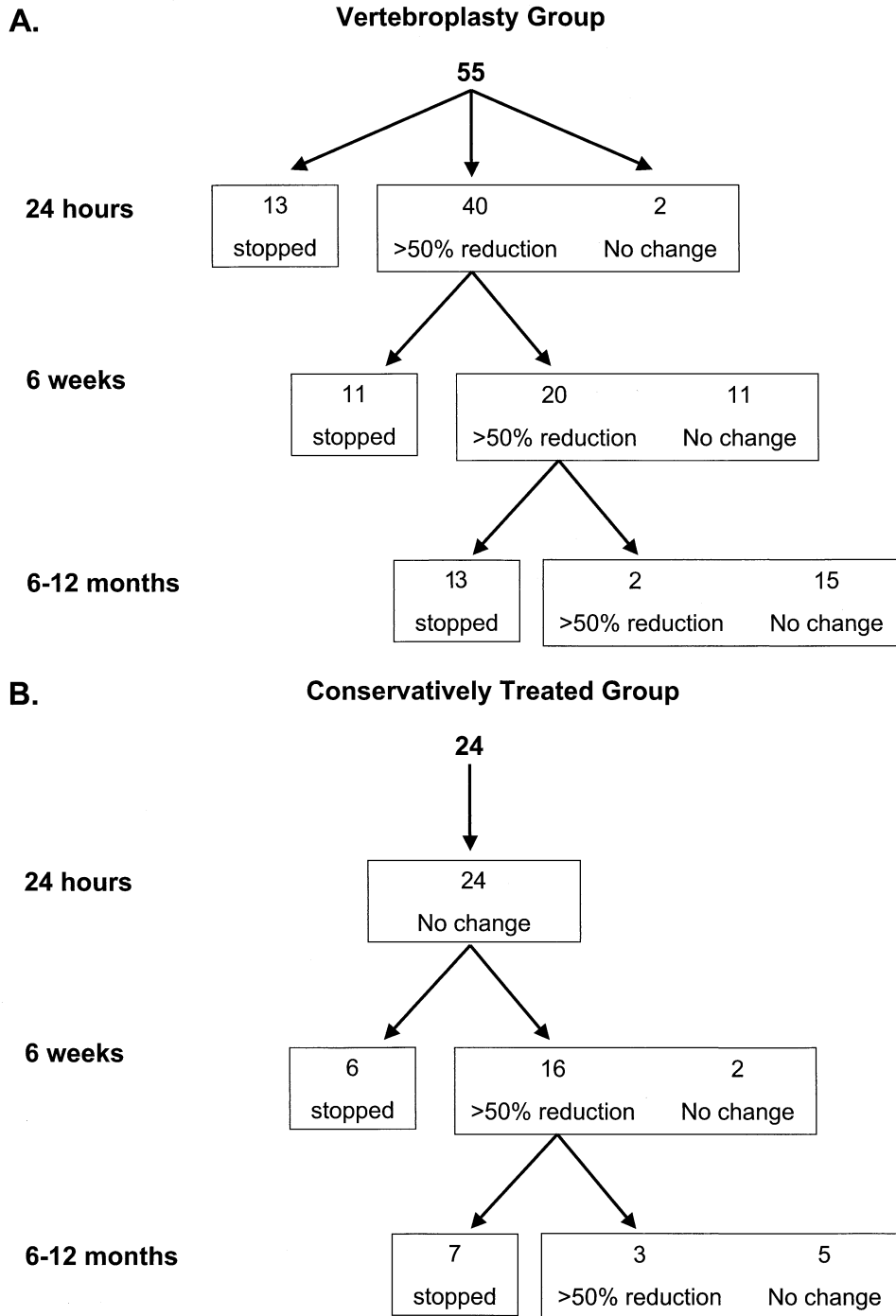
Twenty-four hours after vertebroplasty, patients reported a 53% reduction in pain score and a 29% improvement in physical functioning, as compared with no changes in these outcomes among patients treated conservatively (both  $P = 0.0001$ ; Table 2, Figure 2). Thirteen patients (24%) treated by percutaneous vertebroplasty were able to cease all analgesia after 24 hours ( $P = 0.0001$  as compared with none of the 24 patients treated conservatively; Figure 3). Clinical outcomes at 6 weeks and 6 to 12 months were similar in both groups (Figures 2 and 3).

Subgroup analyses within the percutaneous vertebroplasty group showed similar changes in pain scores and physical functioning in men and women, hospital inpatients and outpatients, vitamin D-deficient and vitamin D-replete patients, corticosteroid- and noncorticosteroid-treated patients, and pamidronate- and alendronate-treated patients. Patients who underwent vertebroplasty for lumbar fractures had a greater improvement in physical functioning at 24 hours ( $P = 0.02$ ; from 12 to 18, an improvement of 50%) than did those with thoracic fractures (from 16 to 19, an improvement of 19%).

The mean ( $\pm$  SD) length of stay among the 29 inpatients treated by percutaneous vertebroplasty was  $9 \pm 6$  days, 40% less than the mean of  $15 \pm 6$  days among the 13 inpatients treated conservatively ( $P = 0.01$ ).

## DISCUSSION

Until recently, bed rest, narcotic analgesia, and physical support were the only treatments for acute vertebral



**Figure 3.** Flow diagram demonstrating the cumulative reduction in analgesia requirements in patients treated by percutaneous vertebroplasty (A) or conservative therapy alone (B). Two men in the vertebroplasty group and 3 women in the conservatively-treated group died before evaluation at 6 months.

compression fractures, and these had limited efficacy (21). Percutaneous vertebroplasty, which was designed for treating aggressive angiomas, bone metastases, and myeloma (8,22), has been used increasingly for the management of acute osteoporotic vertebral fractures (3–14).

However, previous studies have been short in duration and have not had a comparison group of patients treated with usual care. In this nonrandomized study, with a mean follow-up of 215 days, we compared the clinical outcomes of 55 patients with acute osteoporotic vertebral

compression fractures who had undergone percutaneous vertebroplasty with those in 24 patients treated with conservative therapy alone.

Several longitudinal studies (7,9,11) have evaluated the benefits of percutaneous vertebroplasty with validated outcome measures. In our study, prompt reductions in pain scores and improvements in physical functioning were noted 24 hours after percutaneous vertebroplasty, as compared with patients treated conservatively. More patients who were treated with vertebroplasty were able to stop analgesic medications within 24 hours, and length of stay was shorter among patients who underwent the procedure. Both groups, however, had similar improvements in clinical outcomes at 6 weeks, and 6 to 12 months later.

The benefits of percutaneous vertebroplasty depend on patient selection, operator skills, and complication rates. However, there are no definite criteria for selecting ideal patients, or when to perform vertebroplasty. Faciszewski et al. (23) have suggested that the characteristics of a vertebral compression fracture, including morphology, chronicity, reparative activity, dynamic stability, intravertebral trabecular disruption, and violation of the posterior cortical wall, are essential for patient selection. Contraindications to percutaneous vertebroplasty include coagulation disorders, osteomyelitis, vertebra plana, and the presence of severely retropulsed vertebral fracture fragments. We elected to perform the procedure as early as 1 to 2 weeks after fracture because many of the patients were unable to cope with the pain. Early vertebroplasty may also prevent further height loss in the affected vertebra, although this hypothesis remains untested. There are no published studies comparing early and delayed vertebroplasty.

Percutaneous vertebroplasty is not without risk and should be undertaken in specialized centers (13,15). Potential complications (13), which may be more common in patients with tumors, include perivertebral venous migration of cement resulting in pulmonary cement emboli, and epidural cement extravasation, causing spinal cord or nerve root compression and infection. These complications can be avoided by using adequately viscous cement, sterile technique, and high-grade digital fluoroscopy. In our study, 3 patients had minor complications following vertebroplasty, including fractured transverse process and hemorrhage. Similar complications have been noted in other studies (5,7,9).

The effects of vertebroplasty on the risk of future fractures is not known (9,13). Adjacent vertebrae may be at increased risk, particularly if cement extravasates into the disc. Grados et al. (9) reported a nonsignificant 1.4-fold increase in the risk of new vertebral fractures adjacent to vertebroplasty. However, patients with vertebral osteoporosis have a markedly increased risk of additional fractures (24); thus, it is not clear if there is an increased risk

associated with vertebroplasty. In our study, 3 patients treated with percutaneous vertebroplasty sustained recurrent fractures at sites not adjacent to the previously fractured vertebra. Future long-term studies with sufficient statistical power are essential to determine the fracture risk associated with percutaneous vertebroplasty.

Percutaneous vertebroplasty can only be declared "effective" if it is compared with a sham procedure (25), but there have not been any well-designed randomized trials comparing percutaneous vertebroplasty with a sham procedure. To resolve this issue, two study groups would be required, comprising a sham group (treated by "sham vertebroplasty") and an intervention group (treated by percutaneous vertebroplasty). This study design raises ethical concerns, and Watts et al. (14) have suggested that an alternative would be to randomly assign patients to undergo vertebroplasty either immediately or after a 2- to 4-week delay. We selected a conservatively treated group of patients as controls for our study. Their management did not differ from accepted clinical guidelines (26). The drawbacks of our study included the nonrandomized design, the small number of controls, and the relatively short period of observation.

In conclusion, our results suggest that the pain and disability of acute osteoporotic vertebral compression fractures appear to be treated more effectively by percutaneous vertebroplasty than by conservative therapy alone. Vertebroplasty appears to be safe and well tolerated by patients. Carefully designed and well-executed long-term clinical trials are needed to verify that percutaneous vertebroplasty is effective and superior to conservative therapy for managing acute osteoporotic vertebral fractures.

## REFERENCES

1. Ross P. Clinical consequences of vertebral fractures. *Am J Med.* 1997;103(suppl):30S-43S.
2. Center JR, Nguyen TV, Schneider D, et al. Mortality after all major types of osteoporotic fracture in men and women: an observational study. *Lancet.* 1999;353:878-882.
3. Cotton A, Boutry N, Cortet B, et al. Percutaneous vertebroplasty: state of the art. *Radiographics.* 1998;18:311-320.
4. Deramond H, Depriester C, Galibert P, Le Gars D. Percutaneous vertebroplasty with polymethylmethacrylate: technique, indications and results. *Radiol Clin North Am.* 1998;3:533-546.
5. Cortet B, Cotton A, Boutry N, et al. Percutaneous vertebroplasty in the treatment of osteoporotic vertebral compression fractures: an open prospective study. *J Rheumatol.* 1999;26:2222-2228.
6. Cyteval C, Baron Sarrabere MP, Roux JO, et al. Acute osteoporotic vertebral collapse: open study on percutaneous injection of acrylic surgical cement in 20 patients. *AJR Am J Roentgenol.* 1999;173:1585-1590.
7. Martin JB, Jean B, Sugiu K, et al. Vertebroplasty: clinical experience and follow-up results. *Bone.* 1999;25(suppl):11S-15S.
8. Barr JD, Barr MS, Lemley TJ, McCann RM. Percutaneous vertebroplasty for pain relief and spinal stabilisation. *Spine.* 2000;25:923-928.

9. Grados F, Depriester C, Cayrolle G, et al. Long-term observations of vertebral osteoporotic fractures treated by percutaneous vertebroplasty. *Rheumatology*. 2000;39:1410–1414.
10. Jensen ME, Dion JE. Percutaneous vertebroplasty in the treatment of osteoporotic compression fractures. *Neuroimaging Clin N Am*. 2000;10:547–569.
11. Diamond TH, Clarke WA. Percutaneous vertebroplasty: a novel treatment for acute vertebral fractures. *Med J Aust*. 2001;174:398–400.
12. Mathis JM, Barr JD, Belkoff SM, et al. Percutaneous vertebroplasty: a developing standard of care for vertebral compression fractures. *Am J Neuroradiol*. 2001;22:373–381.
13. Murphy KJ, Lin DDM. Vertebroplasty: a simple solution to a difficult problem. *J Clin Densitom*. 2001;4:189–197.
14. Watts NB, Harris ST, Genant HK. Treatment of painful osteoporotic vertebral fractures with percutaneous vertebroplasty or kyphoplasty. *Osteoporos Int*. 2001;12:429–437.
15. Anderson JM. Percutaneous vertebroplasty: a novel treatment for acute vertebral fractures [letter]. *Med J Aust*. 2001;175:54.
16. Lewiecki EM. Vertebroplasty and kyphoplasty in 2001. *J Clin Densitom*. 2001;4:185–187.
17. Diamond T, Campbell J, Bryant C, Lynch W. The effect of combined androgen blockade on bone turnover and bone mineral densities in men treated for prostate carcinoma. *Cancer*. 1998;83:156–162.
18. Genant HK, Wu CY, Van Kuijk C, Nevitt MC. Vertebral fracture assessment using a semiquantitative technique. *J Bone Miner Res*. 1993;8:1137–1148.
19. Melzack R. The McGill Pain Questionnaire: major properties and scoring methods. *Pain*. 1975;1:275–279.
20. Mahoney F, Barthel H. The Barthel Index. *Maryland State Med J*. 1965;14:61–65.
21. Tamayo-Orozco J, Arzac-Palumbo P, Peon-Vidales H, et al. Vertebral fractures associated with osteoporosis: patient management. *Am J Med*. 1997;103(suppl):44S–50S.
22. Murphy KJ, Deramond H. Percutaneous vertebroplasty in benign and malignant disease. *Neuroimaging Clin N Am*. 2000;10:535–545.
23. Faciszewski T, McKiernan F. Calling all vertebral fractures—classification of vertebral compression fractures: a consensus for comparison of treatment and outcome. *J Bone Miner Res*. 2002;17:185–191.
24. Melton LJ, Atkinson EJ, Cooper C, et al. Vertebral fractures predict subsequent fractures. *Osteoporosis Int*. 1999;10:214–221.
25. Macklin R. The ethical problems with sham surgery in clinical research. *N Engl J Med*. 1999;341:992–996.
26. Siris E. Alendronate in the treatment of osteoporosis: a review of the clinical trials. *J Womens Health Gen Based Med*. 2000;9:599–606.