

New Technologies in Spine

Kyphoplasty and Vertebroplasty for the Treatment of Painful Osteoporotic Compression Fractures

Steven R. Garfin, MD,* Hansen A. Yuan, MD,† and Mark A. Reiley, MD‡

Study Design: Literature review

Objectives: To describe new treatments for painful osteoporotic compression fractures in light of available scientific literature and clinical experience.

Summary of Background Data. Painful vertebral osteoporotic compression fractures lead to significant morbidity and mortality. This relates to pulmonary dysfunction, eating disorders (nutritional deficits), pain, loss of independence, and mental status change (related to pain and medications). Medications to treat osteoporosis (primarily antiresorptive) do not effectively treat the pain or the fracture, and require over 1 year to reduce the degree of osteoporosis. Kyphoplasty and vertebroplasty are new techniques that help decrease the pain and improve function in fractured vertebrae.

Methods. This is a descriptive review of the background leading to vertebroplasty and kyphoplasty, a description of the techniques, a review of the literature, as well as current ongoing studies evaluating kyphoplasty.

Results: Both techniques have had a very high acceptance and use rate. There is 95% improvement in pain and significant improvement in function following treatment by either of these percutaneous techniques. Kyphoplasty improves height of the fractured vertebra, and improves kyphosis by over 50%, if performed within 3 months from the onset of the fracture (onset of pain). There is some height improvement, though not as marked, along with 95% clinical improvement, if the procedure is performed after 3 months. Complications occur with both and relate to cement leakage in both, and cement emboli with vertebroplasty.

Conclusion: Kyphoplasty and vertebroplasty are safe and effective, and have a useful role in the treatment of painful osteoporotic vertebral compression fractures that do not respond to conventional treatments. Kyphoplasty offers the additional advantage of realigning the spinal column and regaining height of the fractured vertebra, which may help decrease the pulmonary, GI, and early morbidity consequences related to these fractures. Both procedures are technically demanding. [Key words: osteoporotic vertebral compression fractures, kyphoplasty, vertebroplasty] **Spine 2001;26:1511–1515**

Liebschner et al present their early clinical results. In this review, we attempt to highlight the important issues around the early results of this relatively new technique of treating painful nonpathologic vertebral compression fractures.

A painful osteoporotic vertebral fracture can be a significant burden for patients (and their families), impairing physical function and quality of life.^{9,18} Independent of pain, there is morbidity associated with the spinal deformity.^{4,9} In the thoracic spine this is due to decreased lung capacity (FVC and FEV1).^{14,20} In the lumbar spine compression fractures also affect lung capacity,²⁰ probably due to restrictive airway disease caused by loss of height, and lead to a reduction in abdominal space associated with loss of appetite¹⁹ and secondary sequelae related to poor nutrition. Additionally, vertebral body compression fractures (VCFs) cause chronic pain, sleep loss, decreased mobility, depression, and a loss of independence.^{3,10,16,19,21} The medications taken for symptomatic relief can lead to further mood or mental alterations that compound the medical condition. A large prospective study noted a 23% increase in mortality in women older than 65 years with VCFs compared with age-matched controls. The mortality rate increases with the number of vertebrae fractured.¹² Most painful VCFs are treated palliatively, with bed rest, narcotic analgesics, orthotics, and time. However, bed rest accelerates bone loss^{2,23} and leads to muscle deconditioning,² resulting in increased pain from both of these mechanisms. The other treatments for osteoporosis (e.g., hormone replacement, bisphosphonates, calcitonin) are important for the long-term treatment of this disease but often do not provide short-term pain relief.

There are, however, new minimally invasive techniques that have been developed to help stabilize the fractured vertebra and, more importantly, decrease the pain and improve the function of individuals debilitated by painful osteoporotic VCFs. Vertebroplasty provides stabilization and pain relief without deformity improvement. Kyphoplasty helps realign the fractured vertebra (Figures 1–8), thereby decreasing the kyphosis and creating a void that theoretically allows safer introduction of polymethylmethacrylate (PMMA) into the fractured vertebra.

■ Methods

Vertebroplasty is the percutaneous injection of PMMA into a fractured vertebral body through one or two bone biopsy needles. It was developed to stabilize the spine, increase mobility, and decrease the pain from symptomatic VCFs caused by me-

In this issue of Spine there are several papers dealing with the topic of vertebroplasty and kyphoplasty. Several of the papers deal with basic biomechanical research, while

From the *University of California, San Diego, California, †SUNY Health Centers, Syracuse, New York, and ‡Berkeley Orthopaedic Medical Group, Inc., Berkeley, California.

The KypX balloon bone tamp used for kyphoplasty is approved by the FDA for reduction of fractures in long bones and the spine. Polymethylmethacrylate is approved for use in joint reconstruction. Its use in the spine is off label.

Acknowledgment date: July 25, 2000.

First revision date: October 23, 2000.

Acceptance date: July 24, 2001.

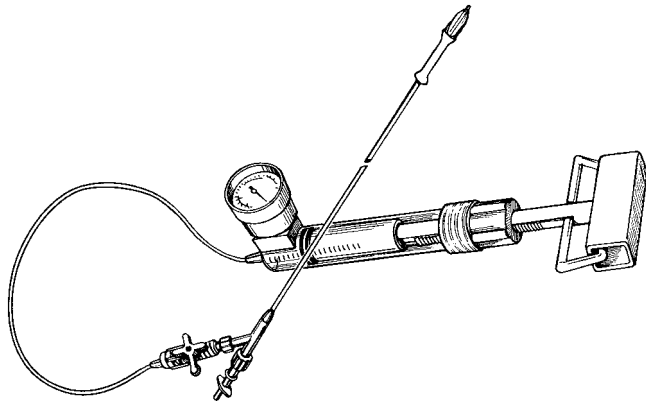


Figure 1. Drawing of bone tamp attached to a digital manometer.

tastases, angiomas, and osteoporosis.^{8,13} However, vertebroplasty does not address the spinal deformity with its associated morbidity. Also, because PMMA is forced into the cancellous bone matrix, high pressures and runny cement are required, with potential for leaks.

Kyphoplasty involves inserting a bone tamp/balloon (Figure 2) into the vertebral body under image guidance. When inflated with radiocontrast medium (for visualization), the inflatable bone tamp compacts the cancellous bone and reexpands the body. When positioned properly, this technique elevates the

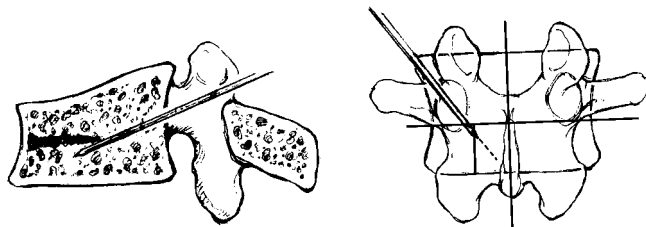


Figure 2. Drawing of a guide pin entering the pedicle in the lateral (left) and anteroposterior (right) plane.

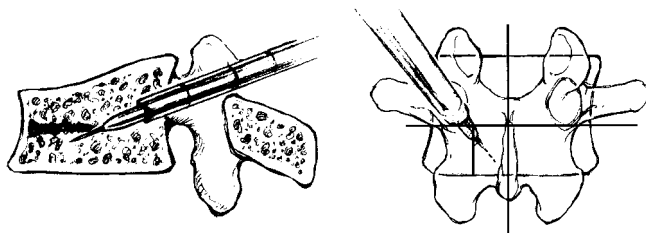


Figure 3. A stylet and cannula are placed over the guide pin into the pedicle.

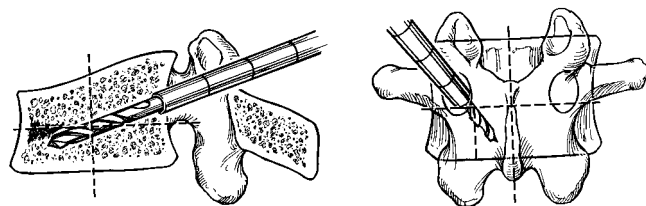


Figure 4. The guide pin and stylet are removed. This is followed by a hand-driven drill to create a larger channel in the bone.

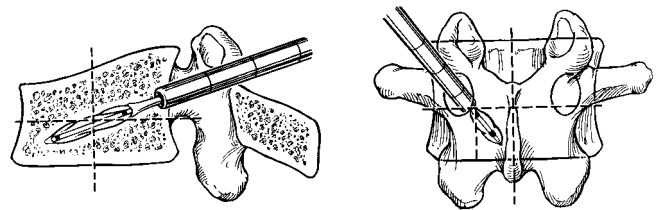


Figure 5. The drill is removed and the bone tamp is then inserted.

endplates without expanding the fractured vertebral body laterally or posteriorly. Two balloons are generally used to provide *en masse* reduction. Rupture of the balloon (which rarely occurs) is not a hazard, other than exposure to small volumes of radiocontrast medium. Because of the balloons, kyphoplasty allows some correction of the kyphotic deformity by reexpanding the fractured vertebra. The cavity created by the balloons facilitates the controlled placement of thick PMMA under low pressure. This should decrease associated risks related to the deformity, increase filling control, and stabilize the vertebra, thereby safely decreasing pain and improving mobility.

Both techniques start with the percutaneous insertion of a needle (usually 11 G) or guide pin into the fractured vertebra and end with the injection of PMMA. This can be through a transpedicular approach in nearly every case. In the thoracic spine the needle can be inserted extrapedicularly, between the rib head and lateral aspect of the pedicle. In the midlumbar

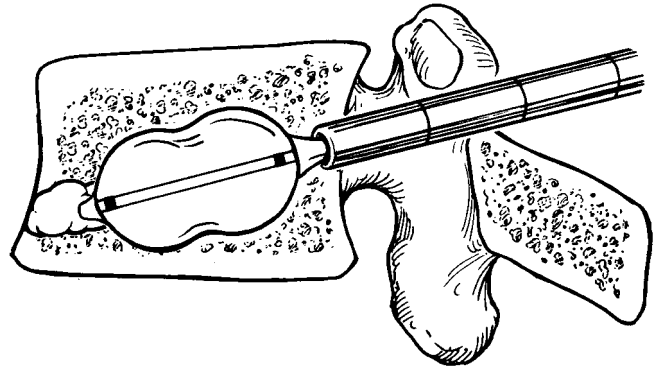


Figure 6. The balloon is inflated. This creates a cavity and compacts the bone around the balloon, elevating the fractured cortices.

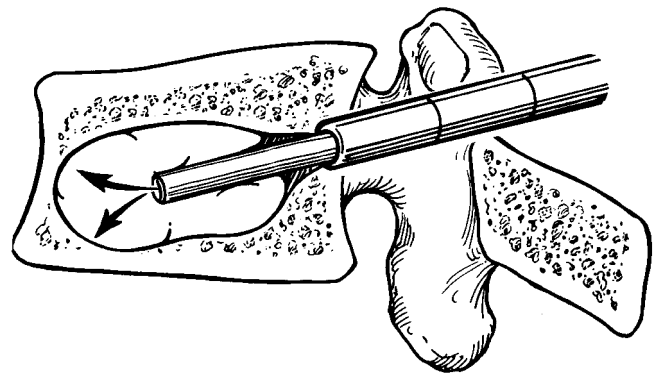


Figure 7. The balloon is removed, a bone filler device is inserted through the cannula, and cement is injected (packed) into the void.

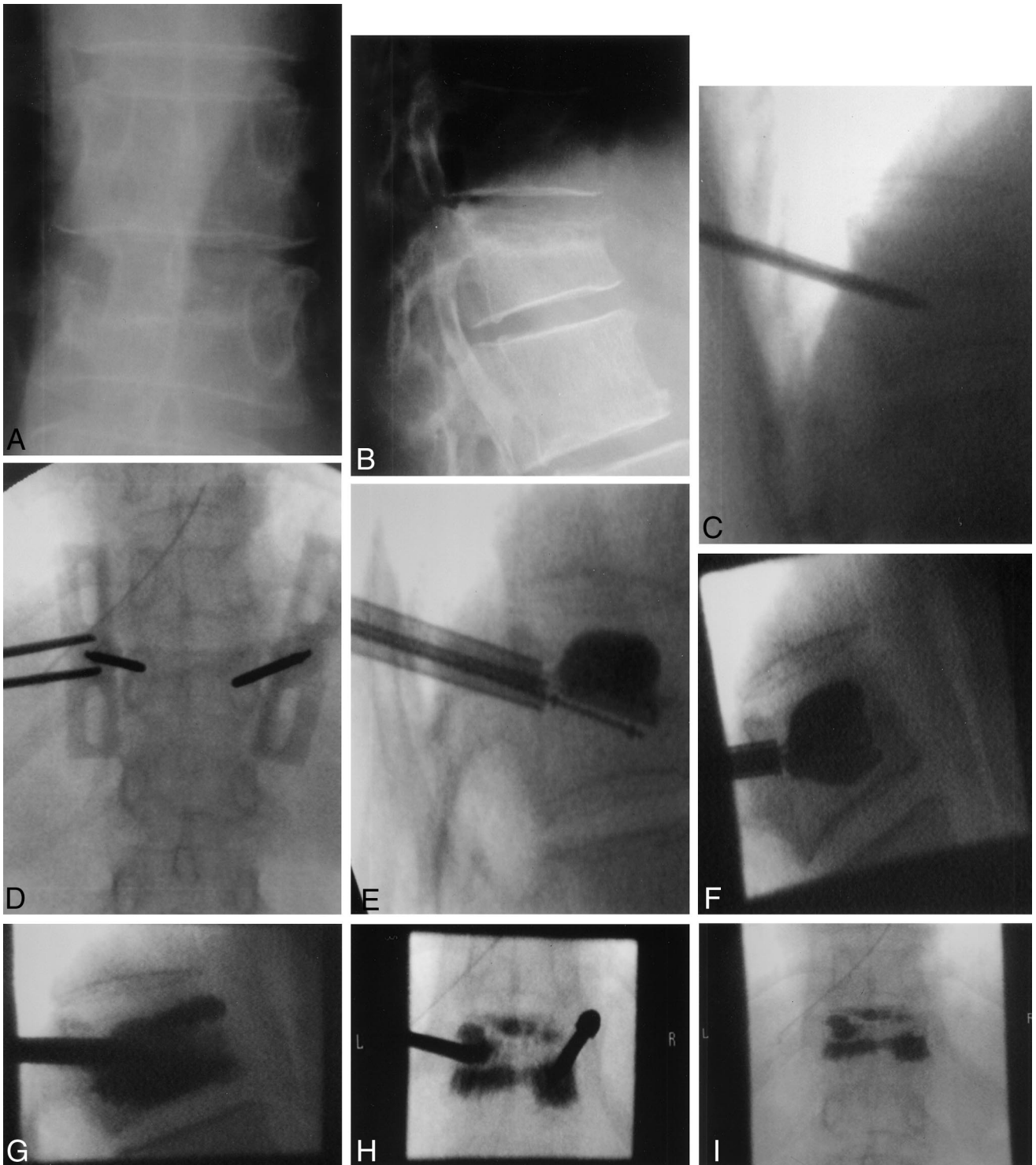


Figure 8. An 87-year-old woman with a T12 compression fracture, with 2 months of acute, debilitating pain. Within a day of kyphoplasty, the patient had significant pain relief. Within 2 weeks she returned to all normal activities and on no medications. Anteroposterior (**A**) and lateral (**B**) view of T12 fracture. The sclerotic line in the midportion of T12 (on lateral) delineates an old fracture from a newer fracture (the superior portion). Lateral (**C**) and anteroposterior (**D**) image of the guide pins in the pedicles. **E**, A lateral view with balloon tamps in place. One has undergone initial inflation, and the second is in position but not yet inflated (the lower single line with two marker dots, denoting ends of the balloon). **F**, Both balloons are inflated. The height of the body has increased and the end-plate is straighter (compare with **B**). A lateral (**G**) and anteroposterior (**H**) view with cement in the vertebral body and the bone filling devices in place. Vertebral body height is improved from pre-reduction film. **I**, Anteroposterior view with cement in place. Note the superior line of cement that has filled the cleft that was created between the old and new fractures (compare with **B**).

spine a posterolateral approach can be used. Unless a lumbar posterolateral approach is used, a bilateral injection should be performed (although in the laboratory unilateral injections have been shown to provide stable internal fixation²²). Fluoroscopy (C-Arm) is used to localize the insertion site and position of the cannula. Local, regional, or general anesthetic can be used.

For vertebroplasty, after correct positioning of the needle, the inner stylet is removed. Contrast material is then injected to assure that the needle is not positioned in the venous flow path. If this occurs, the needle should be repositioned. Injection of PMMA into the venous flow path could result in PMMA embolism or leakage into the spinal canal. Cement, in a thin liquid form, is injected using multiple small syringes (for maximum hand pressure) into the vertebra. The flow of the cement should be followed on the image intensifier. Approximately 1–4 mL per side can usually be accepted.

For kyphoplasty, after proper needle positioning, a series of tools are used to create a working channel. Once inserted, the balloons are then inflated using visual (radiographic), volume, and pressure controls (digital manometer) to create a cavity within the vertebra and to reduce the fracture deformity. Once this has been achieved, the balloons are deflated and removed. Thick cement can be fed through the cannula under low pressure to fill the void created by the balloon tamp. A total of 2–6 mL per side can usually be inserted.

■ Results

Prospective studies have shown significant improvement in mobility and function after treatment.^{5,7,15} The literature on percutaneous vertebroplasty reports success rate in pain relief of approximately 70–90%.^{1,5–7,11,24} Most of the studies have only a small number of patients and limited follow-up. Also, none was randomized or controlled comparing this treatment with standard medical therapy.

Kyphoplasty has only been used actively in the last few years since the FDA approved the inflatable bone tamps in 1998. In an ongoing multicenter study from October 1998 through May 2000, 603 fractures have been reduced and treated by the kyphoplasty technique in the United States. This involved 376 procedures on 340 patients. Early results (with the longest follow-up at 18 months) demonstrate a 90% symptomatic and functional improvement rate. The average anterior height was $83 \pm 14\%$ of predicted height before treatment and $99 \pm 13\%$ of predicted height after treatment ($P < 0.01$). The average midline height was $76 \pm 14\%$ before treatment and $92 \pm 11\%$ after treatment ($n = 17, P < 0.05$). In vertebral bodies with 15% or more of the estimated height lost, the average anterior height improved from $68 \pm 12\%$ of predicted height before treatment to $84 \pm 14\%$ of predicted height after treatment ($P < 0.01$). The average midline height was $64 \pm 13\%$ before treatment and $90 \pm 12\%$ after treatment ($P < 0.01$). The average posterior height was $74 \pm 12\%$ before treatment and $88 \pm 14\%$ after treatment ($P < 0.05$). In both techniques the hospital stay has been short (1–3 days), with many performed as outpatient procedures. Most patients have

gone from narcotic analgesics to over-the-counter medications.

Complications

Vertebroplasty Reported significant complications are low (less than 10%) and include increased pain, radiculopathies, spinal cord compression, pulmonary embolism, infection, and rib fractures.^{5,6,11,17,22,24} Cement leakage, where reported, is common (from 30% to 67%^{1,6,7,24}) but does not generally lead to clinical complications. Cement leakage leading to radiculopathy or spinal cord injury is more common after the treatment of pathologic fractures relating to metastasis or myeloma than for osteoporotic fractures. In the largest report on osteoporotic fractures, the rate of radiculopathy was 4% and the rate of cord compression was less than 0.5%.¹ The majority of reported symptoms were transient.

Kyphoplasty To date, there have been four important complications in these procedures caused by the devices (0.7% per fracture and 1.2% per patient). One patient has had transient fever and hypoxia after placement of PMMA in a liquid form. One patient had an epidural hematoma when a heparin bolus was administered 8 hours postoperatively. Surgical evacuation led to full recovery. One patient had partial motor loss to the lower extremities because of the position of the cement-filling device, with some of the cement delivered into the spinal canal. Surgical decompression was performed and significant recovery occurred. One patient developed an anterior cord syndrome when the extrapedicular approach was used in a patient whose vertebra had fractured through the pedicle–body junction. In this case the body was below the pedicle, making needle insertion difficult. To date, the complications have been related to the needle insertion, not the balloon tamps per se.

■ Discussion

Vertebroplasty and kyphoplasty are techniques that result in pain relief with a low rate of major complications, for the treatment of painful osteoporotic vertebral compression fractures. Additionally, kyphoplasty reduces acute fractures and allows the controlled placement of PMMA, resulting in improvement of deformity in addition to pain. In appropriately selected patients these treatments provide a means for rapid pain relief and rehabilitation while awaiting the later benefits of medical intervention for the osteoporosis. PMMA is currently the stabilizing bone filler of choice. It has been used successfully to fill defects created by tumors of bone with good long-term outcomes and no cement failures or fractures in vertebra as well as other bones. Modifications will most likely occur to the PMMA, providing packaging in appropriate sizes and altered curing capability for this specific treatment. Additionally, newer pharmaceuticals (which should be bioresorbable) and the development of a bioresorbable balloon to obviate the need to remove it (thereby improving safety and diminishing the likelihood

of any leakage of the substrate) are important and hopefully will be developed soon. The early results for both techniques are promising. However, rigorous study to determine efficacy and safety is needed in both techniques. Also, importantly, a better understanding of the natural history of the disorder, when to intervene in the treatment process, and whether maintaining or improving alignment will decrease medical complications of the deformity itself need to be studied. These treatments do provide significant functional and pain improvement to otherwise debilitated, often elderly, individuals.

■ Key Points

- Osteoporotic vertebral compression fractures have a relatively high morbidity and mortality (often unappreciated).
- Kyphoplasty and vertebroplasty lead to 95% improvement in pain and significant functional improvement in individuals not responding to conventional treatments.
- Kyphoplasty improves fractured vertebral body height and decreases kyphosis by 50%, if performed within 3 months of the onset of the pain.
- Kyphoplasty is associated with less cement leakage than vertebroplasty (these tend to be relatively clinically insignificant in both procedures).
- There is a potential for significant complications from both procedures (pulmonary, gastrointestinal, vascular, and spinal cord and cauda equina injuries).

References

1. Chiras J. Percutaneous vertebral surgery: techniques and indications. *J Neuro-radiol* 1997;24:45–52.
2. Convertino VA, Bloomfield SA, Greenleaf JF. An overview of the issues: physiological effects of bed rest and restricted physical activity. *Med Sci Exerc* 1997;29:187–90.
3. Cook DJ, Guyatt GH, Adachi JD, et al. Quality of life issues in women with vertebral fractures due to osteoporosis. *Arthritis Rheum* 1993;36:750–6.
4. Cooper C, Atkinson EJ, Jacobsen SJ, O'Fallon WM, Melton LJ III. Incidence of clinically diagnosed vertebral fractures: a population-based study in Rochester, Minnesota, 1985–1989. *J Bone Miner Res* 1993;7:221–7.
5. Cortet B, Cotton A, Boutry R, et al. Percutaneous vertebroplasty in the treatment of osteoporotic vertebral compression fractures: an open prospective study. *J Rheum* 1999;26:2222–8.
6. Cotton A, Dewatre F, Cortet B, et al. Percutaneous vertebroplasty for osteolytic metastases and myeloma: effects of the percentage of lesion filling and the leakage of methyl methacrylate at clinical follow-up. *Radiology* 1996;200:525–30.
7. Deramond H. Percutaneous vertebroplasty with polymethylmethacrylate: technique, indications and results. *Radiol Clin North Am* 1998;36:533–46.
8. Galibert P. Note préliminaire sur le traitement des angiomes vertébraux par vertébroplastie acrylique percutanée. *Neurochirurgie* 1987;33:166–7.
9. Garfin S, Yuan H, Lieberman I, Reiley M. Early outcomes in the minimally invasive reduction and fixation of compression fractures. American Academy of Orthopaedic Surgeons Annual Meeting, San Francisco, California, 2001.
10. Gold DT. The clinical impact of vertebral fractures: quality of life in women with osteoporosis. *Bone* 1996;18(suppl):185–9.
11. Jensen ML. Percutaneous polymethylmethacrylate vertebroplasty in the treatment of osteoporotic vertebral body compression fractures: technical aspects. *Am J Neuroradiol* 1997;18:1897–904.
12. Kado DM, Browner WS, Palermo L, Nevitt MC, Genant HK, Cummings SR. Vertebral fractures and mortality in older women: a prospective study. Study of Osteoporotic Fractures Research Group. *Arch Intern Med* 1999;159:1215–20.
13. Lapras J, Mottolèse C, Deruty R, et al. Injection percutané de méthyl-méthacrylate dans le traitement de l'ostéoporose et ostéolyse vertébrale grave. *Ann Chir* 1987;43:371–5.
14. Leech JA, Dulberg C, Kellie S, Pattee L, Gay J. Relationship of lung function to severity of osteoporosis in women. *Am Rev Respir Dis* 1990;141:68–71.
15. Lieberman I, Dudeney S, Reinhardt M. Initial outcome and efficacy of kyphoplasty in the treatment of painful osteoporotic vertebral compression fractures. *Spine* 2001;26:1631–8.
16. Nevitt MC, Ettinger B, Black DM, et al. The association of radiographically detected vertebral fractures with back pain and function: a prospective study. *Ann Intern Med* 1998;15:793–800.
17. Padovani B, Kasriel O, Brunner P, Peretti-Viton P. Pulmonary embolism caused by acrylic cement: a rare complication of percutaneous vertebroplasty. *AJNR Am J Neuroradiol* 1999;20:375–7.
18. Riggs LR, Melton LJ. The worldwide problem of osteoporosis: lessons from epidemiology. *Bone* 1995;17:505S–11S.
19. Ross PD, David JW, Epstein RS, Wasnich RD. Pain and disability associated with new vertebral fractures and other spinal conditions. *J Clin Epidemiol* 1994;47:234–9.
20. Schlaich C, Minne HW, Bruckner T, et al. Reduced pulmonary function in patients with spinal osteoporotic fractures. *Osteoporos Int* 1998;8:261–7.
21. Silverman S. The clinical consequences of vertebral compression fracture. *Bone* 1992;13(suppl):27–32.
22. Tomeh AG, Mathis JM, Fenton DC, Levine AM, Belkoff SM. Biomechanical efficacy of unipedicular versus bipedicular vertebroplasty for the management of osteoporotic compression fractures. *Spine* 1999;24:1772–6.
23. Uthoff HK, Jaworski ZF. Bone loss in response to long term immobilization. *J Bone Joint Surg Br* 1978;60:420–9.
24. Weill A, Chiras J, Simon JM, Rose M, Sola-Martinez T, Enkaoua E. Spinal metastases: indications for and results of percutaneous injection of surgical cement. *Radiology* 1996;199:241–7.

Address reprint requests to

Steven R. Garfin, MD
 Department of Orthopaedics
 UCSD Medical Center
 200 West Arbor Drive
 San Diego, CA 92103-8894
 E-mail: SGARFIN@UCSD.EDU